

# Success rates of Hall technique crowns in primary molars: a retrospective pilot study

Walker Clark, DDS ■ Matthew Geneser, DDS ■ Arwa Owais, BDS, MS ■ Michael Kanellis, DDS, MS  
Fang Qian, PhD

The purpose of this retrospective observational study was to assess success rates, both clinical and radiographic, of stainless steel crowns (SSCs) placed on primary molars using the Hall technique. A retrospective analysis was performed on recorded data of patients with any primary molar treated with an SSC that was placed using the Hall technique at the University of Iowa College of Dentistry during 2011-2015. The primary outcome measure was the success or failure of the SSCs placed with the Hall technique. These outcomes were categorized as either clinical and radiographic success or failure. Clinical failure was defined as the need for pulp therapy or extraction following crown placement. Radiographic failure was defined as the presence of any pathological condition—including external or internal root resorption, bifurcation radiolucency, widened periodontal ligament, or ectopic eruption of permanent first molar adjacent to the Hall crown—following crown placement. Records indicated that 100 boys received a total of 179 crowns (61.1% of all Hall crowns placed), and 64 girls received 114 crowns. The mean age of the patients was 5.1 years (SD, 2.4 years). Of 293 SSCs included in the study, 180 received at least 1 follow-up examination after a mean of 9.9 months (SD, 6.5 months). At the first follow-up visit, 178 (98.9%) of 180 SSCs placed using the Hall technique were clinically successful. Of 87 crowns with radiographs available, 85 (97.7%) were radiographically successful. At the second follow-up visit (after a mean of 20.1 months), 74 of 76 (97.4%) were rated as clinically successful, and 37 of 39 (94.9%) were radiographically successful. Results of this study provide evidence of high clinical and radiographic success rates for SSCs placed on primary molars with the Hall technique.

**Received:** September 30, 2016

**Revised:** January 14, 2017

**Accepted:** February 7, 2017

Published with permission of the Academy of General Dentistry.  
© Copyright 2017 by the Academy of General Dentistry.  
All rights reserved. For printed and electronic reprints of this article for distribution, please contact [jkaletha@mossbergco.com](mailto:jkaletha@mossbergco.com).

**GENERAL DENTISTRY**  
**SELF-INSTRUCTION**



Exercise No. 408, p. 36

Subject code: Pediatric Dentistry (430)

The Hall technique is an alternative method of treating caries in primary molars by placing a stainless steel crown (SSC) without tooth preparation or caries removal. First discovered by Dr Norna Hall of Scotland, who began using the technique in 1988, this approach has steadily increased in popularity in the United Kingdom and has shown promise in evidence-based research.<sup>1,2</sup> In a 2015 systematic review focused on the use of SSCs, Seale & Randall concluded that the Hall technique has shown validity.<sup>1</sup>

The conventional treatment for a carious primary molar with no evidence of spontaneous pain indicative of irreversible pulpitis is administration of local anesthetic followed by removal of carious tooth structure to achieve retention and resistance for a restorative material such as amalgam, resin-based composite, or resin-modified glass ionomer cement. When retention and resistance form for an intracoronal restoration is unachievable, the use of a stainless steel crown may be required. This conventional model of SSC placement results in further removal of healthy tooth structure to accommodate the crown.

In contrast, in the Hall technique, local anesthesia, removal of caries, and tooth preparations are not required.<sup>3</sup> The tooth is cleaned with an air-water syringe to remove debris and food particles around the tooth, and then an appropriately sized SSC is fitted on the unprepared tooth. The crown is cemented on the tooth with glass ionomer cement.<sup>3</sup>

Although this unconventional technique of leaving active caries challenges conventionally taught methods of tooth preparation and SSC placement, the success rates of crowns placed according to the Hall technique have been found to be comparable to those of teeth treated with conventional methods of complete caries removal. Innes et al structured a split-mouth randomized controlled trial in which matched primary molars with similar lesions were randomly assigned to a conventional treatment group or a Hall technique group.<sup>2</sup> These patients were followed for 2 years, and outcomes were reported as major or minor failures. Major failure was defined as irreversible pulpitis or a tooth that was deemed nonrestorable after treatment. Innes et al reported that 15% (19/124) of the conventional treatment group had a major failure in contrast to only 2% (3/124) of SSCs placed with the Hall technique.<sup>2</sup> In addition, 46% (57/124) of conventionally treated teeth had minor failures, such as restoration failure or reversible pulpitis, while only 5% (6/124) of Hall crowns exhibited these shortcomings.<sup>2</sup>

In 2015, Innes et al published a 5-year retrospective follow-up to the 2007 study.<sup>4</sup> The new data demonstrated that only 50% (48/96) of conventional restorations were successful compared to 91% (88/97) of Hall technique crowns. Major

**Table.** Success and failure rates of Hall crowns.<sup>a</sup>

Parameter	Follow-up	
	First (n = 180)	Second (n = 76)
Mean (SD) follow-up (mo)	9.9 (6.5)	20.1 (9.6)
Clinical failures (No.)	2	2
Clinical success (%)	98.9	97.4
Radiographs obtained (No.)	87	39
Radiographic failures (No.)	2	2
Radiographic success (%)	97.7	94.9
Ectopic eruption (%)	4.8	9.0

<sup>a</sup>The Hall technique was used to place 293 stainless steel crowns in 164 patients (100 boys and 64 girls) with a mean age of 5.1 years (SD, 2.4 years). A single follow-up was recorded for 180 crowns and a second for 76 crowns.

failures, which again included irreversible pulpitis or other indications for premature extraction, were recorded in 21% (20/96) of the conventional treatment group and 4% (4/97) of the Hall crown group, further supporting the data in the initial prospective study.<sup>2,4</sup>

The primary goal of the present retrospective study was to assess the success rates, both clinical and radiographic, of SSCs placed on primary molars using the Hall technique. Secondary to this objective was the intention to evaluate the relationship between placement of Hall crowns and ectopic eruption of adjacent permanent molars.

## Materials and methods

### Selection criteria

Stainless steel crowns placed according to the Hall technique have been completed and recorded for select patients attending pediatric dental clinics at the University of Iowa College of Dentistry since 2011. These procedures have been tracked in AxiUm, the university's electronic dental health record. Records of human subjects were obtained via an AxiUm inquiry of all charts in which placement of a Hall crown was recorded. This search produced a list of patient identification numbers to facilitate access to records. The inclusion criterion was a record of a carious primary molar treated with an SSC that had been placed with the Hall technique. Approval for this study was obtained from the university's Institutional Review Board.

### Baseline and treatment records

Data obtained from the baseline records included detailed information regarding patient demographics, including age, gender, and medical history, as well as diagnostic information, such as the primary molar treated, previous history of pain and/or tenderness to percussion, and current pain status. Preoperative diagnostic radiographs, if available, were analyzed by a calibrated examiner to evaluate the depth of dentinal caries and to determine the presence of any furcation and/or periradicular pathosis prior to treatment.

Archived records of the Hall crown treatment, which was performed at the same visit as the baseline examination for 53.8% of the SSCs, were used to obtain details of the treatment steps, including crown size, cementation technique, and use of orthodontic separators.

### Follow-up records

The results of clinical and radiographic evaluations at each follow-up visit were also recorded. Recorded clinical variables such as pain, crown status, presence or absence of any dental infection related to the treatment provided, and need for any follow-up treatment were obtained from the patient record. Radiographic assessment of follow-up radiographs was performed by a calibrated examiner. The evaluation included assessment of the furcation and periradicular areas of the treated tooth, premature or pathologic resorption, and any subsequent pathoses that affected the survival of the tooth. In addition, radiographic assessment of ectopic eruption of permanent first molars related to the adjacent Hall SSC was recorded.

### Measures of success

The primary outcomes denoting successful treatment were assessed both clinically and radiographically. The case was considered clinically successful if the tooth maintained vitality, had no history of pain or swelling due to irreversible pulpitis, and had no abscess that required pulp therapy or extraction. The case was considered radiographically successful if there was an absence of any pathologic condition, including nonphysiologic root resorption, furcal pathosis, and periapical pathosis, at follow-up visits.

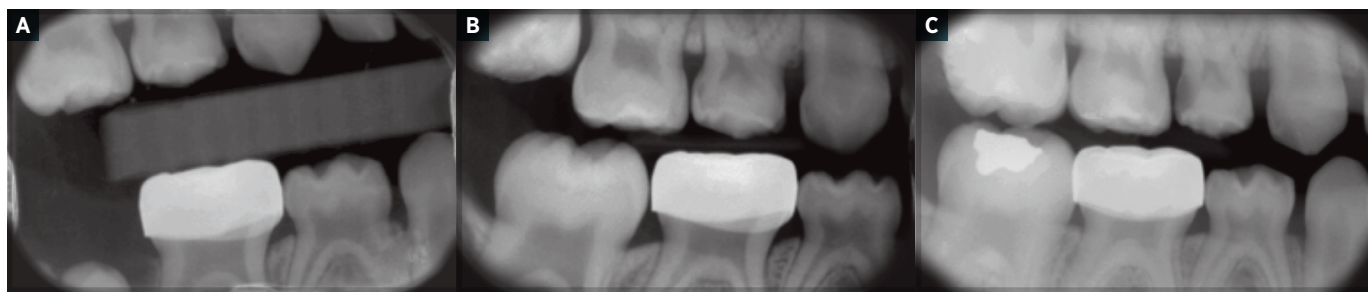
One examiner collected data from all clinical charts, and a single, different examiner performed all radiographic analyses. Therefore, the data collection protocol was consistent, as each type of data was gathered and completed by the same examiner.

## Results

During the years 2011-2015, the Hall technique was used to place 293 SSCs in 164 patients. Records indicated that 100 boys received a total of 179 crowns (61.1% of all Hall crowns placed), and 64 girls received 114 crowns. The mean age at diagnosis was 5.1 years (SD, 2.4 years). Of the 293 SSCs, 180 were reevaluated in at least 1 follow-up examination, which took place a mean of 9.9 months (SD, 6.5 months) after placement (Table). Of those 180 crowns, 76 were evaluated at a second follow-up, which occurred a mean of 20.1 months (SD, 9.6 months) after initial placement.

Among the 180 Hall crowns that were evaluated, there were 4 total clinical failures. At the time of the first follow-up, 98.9% (178/180) of the SSCs were clinically successful, and the teeth had no need for additional treatment that included pulp therapy or extraction. During the second follow-up visit, 97.4% (74/76) of teeth maintained vitality after a mean of 20.1 months with Hall technique SSCs.

Diagnostic radiographs were taken of 48.3% (87/180) of the teeth that underwent at least 1 follow-up. A total of 4 radiographic failures were recorded, each due to ectopic eruption of the permanent first molar. Two failures were identified from the first radiographic follow-up, making 97.7% (85/87) of Hall crowns radiographically successful at that point. At the second



**Figure.** Follow-up radiographs of a stainless steel crown placed with the Hall technique on the primary mandibular right second molar of a 3-year-old child in November 2012. A. October 2013. B. April 2015. The permanent first molar has erupted normally. C. August 2016.

return visit, 51.3% (39/76) of the crowned teeth received radiographs. The other 2 failures were identified from radiographs taken during this time, yielding a 94.9% (37/39) success rate.

Permanent first molars were radiographically evaluated for ectopic eruption, which was potentially caused by Hall crown placement on the primary second molar (Figure). Ectopic eruption was found at incidence rates of 4.8% (2/42) and 9.0% (2/22) during the first and second follow-up visits, respectively.

Bivariate analyses were conducted to determine the factors associated with the clinical and radiographic success rates at each follow-up visit. However, neither demographics nor diagnostic and treatment characteristics were related to the clinical and radiographic success rates ( $P > 0.05$  in each instance).

## Discussion

The efficacy of conventional SSCs has been studied extensively. Randall et al published a systematic review comparing the efficacy of SSCs and amalgam restorations in primary molars.<sup>5</sup> The clinical success rates of 1821 crowns in 10 studies included in their review ranged from 98.1% to 69.7%; the crowns had a weighted average of 90.1% success. Based on the findings of the present study, SSCs placed using the Hall technique show a success rate similar to that of conventional SSCs.

In support of this claim, Ludwig et al recently published a retrospective study comparing the Hall technique to conventional SSC placement.<sup>6</sup> They found no statistically significant difference in success rates between the Hall technique (97% success) and conventional SSCs (94% success).

Not only has there been solid evidence to show that treatment with the Hall technique is successful, but the Hall crown was the treatment approach preferred by both patients and dentists in 2 studies. Innes et al recorded that 72% of children, 73% of dentists, and 63% of parents preferred the Hall technique to conventional methods.<sup>2</sup> Page et al found that 90% of children responded positively and preferred the Hall technique.<sup>7</sup>

The use of the Hall technique for restoration of posterior teeth with Class I and II noncavitated and cavitated lesions has been recorded in the literature.<sup>2,4,6</sup> If the Hall technique is to be used, the tooth must show no signs of irreversible pulpitis or pulpal pathosis and must have enough remaining hard tissue for retention and resistance.<sup>3</sup> These factors assist in proper case selection, which is crucial to success of the Hall crown technique. Conventional treatment, such as pulpotomy or extraction, takes priority when the tooth is symptomatic or abscessed.

Many practitioners have 3 questions regarding the Hall technique: (1) What happens to the caries left in the tooth? (2) How does the crown fit on the unprepared tooth? (3) How does the crown height affect the occlusion? The response to the first question is that the Hall technique arrests caries by sealing the caries under the crown. Once the caries-causing bacteria is sealed from the oral environment, the flora under the crown becomes less active over time, and caries is arrested. Studies that feature a similar mechanism—sealants—have found that active lesions are arrested. Resin sealants arrested clinical progression of active caries in a 10-year evaluation.<sup>8</sup> Comparably, incomplete caries removal procedures that seal caries have been shown to limit caries progression and pulpal necrosis in carious lesions that are near the pulp.<sup>9</sup>

Caries arrest is accomplished as the sealed carious lesion is deprived of the carbohydrate-rich oral environment. Bacteria sensitive to this nutrient-deficient environment decrease in number, and the caries-causing biofilm becomes less metabolic, therefore arresting the disease. As the bacteria become less metabolic, the pulp-dentin complex also has time to increase reparative dentin in the area, preventing future damage to the pulp.<sup>10</sup> The most crucial element to success, therefore, is the complete sealing of the bacteria from the oral environment. If the biofilm under the SSC is not completely sealed, the caries may continue to have access to essential nutrients and may remain cariogenic. Therefore, the fit of the crown plays an important role in the success of the Hall technique. Innes et al found that 97% of crowns fit on unprepared primary molars. However, 15% of these were judged to be incompletely seated.<sup>2</sup>

The second question concerns fitting a crown on an unprepared tooth. The Hall technique, like all dental procedures, is technique sensitive, especially in the presence of tight interproximal contacts. In the study by Innes et al, when tight contacts made it difficult to properly seat the crown, some of the dentists participating in the study placed orthodontic separators to create space for the crown. After 3-5 days, the patient returned to have the crown seated. The use of separators seemed to be based on the preference of the operator, as only 7 of 18 participating dentists used them in 13% of the total cases.<sup>2</sup> Orthodontic separators were not used for any of the 293 SSCs placed in the present study.

The third common question about use of the Hall technique is how the fit of the crown affects the vertical dimension of the tooth in relation to the occlusion. Since no tooth structure is removed, the SSC increases the height of the tooth, which

causes a temporary increase in vertical dimension. Innes et al reported that occlusion was reequilibrated within weeks; when patients returned for follow-up treatment, occlusion was normal.<sup>2</sup> Van der Zee & Van Amerongen similarly found that the mean distance between the overlapping canine tips was 2.45 mm prior to crown placement and 0.54 mm after crown placement.<sup>11</sup> Fifteen days following crown placement the distance was 1.96 mm, and after 30 days the occlusion was equilibrated and measured an average of 2.75 mm. The authors suggested that this outcome was due to the intrusion of the molar and its antagonist rather than the supraeruption of the other teeth.<sup>11</sup>

The present study had some limitations. This study was retrospective, and only 61.4% of the treated SSCs had a recorded follow-up visit. One explanation for this relatively poor return rate is that the University of Iowa College of Dentistry is utilized as a referral and emergency center. Following initial treatment, many children return to local providers for maintenance. The drop-off may have affected the results of the study, because the outcomes of the other 38.6% of SSCs are unknown. This may have introduced a bias favoring those who seek regular dental care and value successful treatment outcomes. However, data collection is ongoing and may improve over time as these children return for recall visits and examination findings are recorded.

Another major limitation of this study is that the Hall crowns were placed by many providers in multiple circumstances. No standardized protocol was used for case selection, treatment, or radiographic technique. Some patients received Hall crowns due to their lack of cooperation, while others received them for the convenience of the provider, making it difficult to control bias and other confounders related to treatment.

## Conclusion

The results of this retrospective study provide important information regarding the outcomes of Hall technique crowns placed on primary molars and confirm the need for future prospective investigation with greater specificity and extended follow-up.

The Hall technique offers relative ease of SSC placement for practitioners and is well accepted by patients and parents. This streamlined, conservative procedure has the potential to improve access to care by increasing the efficiency of specialists and enabling more general practitioners to treat children.

## Author information

Dr Clark is a pediatric dental resident, Primary Children's Hospital, Salt Lake City, Utah. Dr Geneser is a clinical associate professor, Dr Owais is an associate professor, and Dr Kanellis is a professor, Department of Pediatric Dentistry, University of Iowa College of Dentistry, Iowa City, where Dr Qian is an associate research scientist, Division of Biostatistics and Research Design.

## References

1. Seale NS, Randall R. The use of stainless steel crowns: a systematic literature review. *Pediatr Dent*. 2015;37(2):145-160.
2. Innes NP, Evans DJ, Stirrups DR. The Hall Technique; a randomized controlled clinical trial of a novel method of managing carious primary molars in general dental practice: acceptability of the technique and outcomes at 23 months. *BMC Oral Health*. 2007;7:18.
3. Innes N, Evans D. *The Hall Technique: A Minimal Intervention, Child Centred Approach to Managing the Carious Primary Molar. A Users Manual*. 4th version. Dundee, Scotland: University of Dundee; 2015. [https://upload.wikimedia.org/wikipedia/commons/9/91/HallTech-Guide\\_V4.pdf](https://upload.wikimedia.org/wikipedia/commons/9/91/HallTech-Guide_V4.pdf). Accessed June 28, 2017.
4. Innes N, Stewart M, Souster G, Evans D. The Hall technique; retrospective case-note follow-up of 5-year RCT. *Br Dent J*. 2015;219(8):395-400.
5. Randall RC, Vrijhoef MM, Wilson NH. Efficacy of preformed metal crowns vs. amalgam restorations in primary molars: a systematic review. *J Am Dent Assoc*. 2000;131(3):337-343.
6. Ludwig KH, Fontana M, Vinson LA, Platt JA, Dean JA. The success of stainless steel crowns placed with the Hall technique: a retrospective study. *J Am Dent Assoc*. 2014;145(12):1248-1253.
7. Page LA, Boyd DH, Davidson SE, McKay SK, Thomson WM, Innes NP. Acceptability of the Hall Technique to parents and children. *N Z Dent J*. 2014;110(1):12-17.
8. Mertz-Fairhurst EJ, Curtis JW Jr, Ergle JW, Rueggeberg FA, Adair SM. Ultraconservative and cariostatic sealed restorations: results at year 10. *J Am Dent Assoc*. 1998;129(1):55-66.
9. Schwendicke F, Dörfer CE, Paris S. Incomplete caries removal: a systematic review and meta-analysis. *J Dent Res*. 2013;92(4):306-314 [erratum: 2013;92(8):759].
10. Ricketts D, Lamont T, Innes NP, Kidd E, Clarkson JE. Operative caries management in adults and children. *Cochrane Database Syst Rev*. 2013;(3):CD003808.
11. Van der Zee V, Van Amerongen WE. Short communication: influence of preformed metal crowns (Hall technique) on the occlusal vertical dimension in the primary dentition. *Eur Arch Paediatr Dent*. 2010;11(5):225-227.