



**Principles of Third Molar Extractions Techniques**

**Instruments/Armamentarium**

Finger, Wrist, Elbow, & Shoulder Pressure



---

---

---

---

---

---

---

---

**Principles of Third Molar Extractions Techniques**

**Instruments/Armamentarium**

H and H Company 208-719-0861



ELEVATOR X BAR WINTER 14L SKU 10-4714L <b>\$79.00</b>	ELEVATOR X BAR WINTER 14R SKU 10-4714R <b>\$79.00</b>
--	--

---

---

---

---

---

---

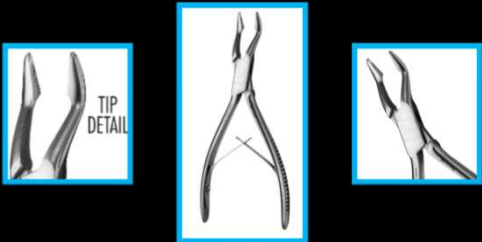
---

---

**Principles of Third Molar Extractions Techniques**

**Instruments/Armamentarium**

Hu-Friedy 3H Dean Rongeurs



End-cutting rongeurs used for trimming and recontouring alveolar bone and gross tissue removal

---

---

---

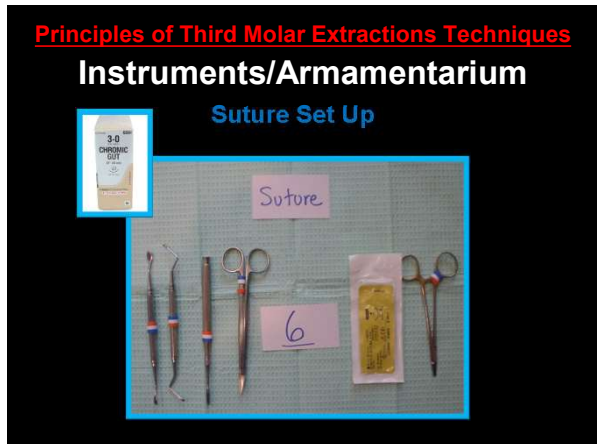---

---

---

---

---



---

---

---

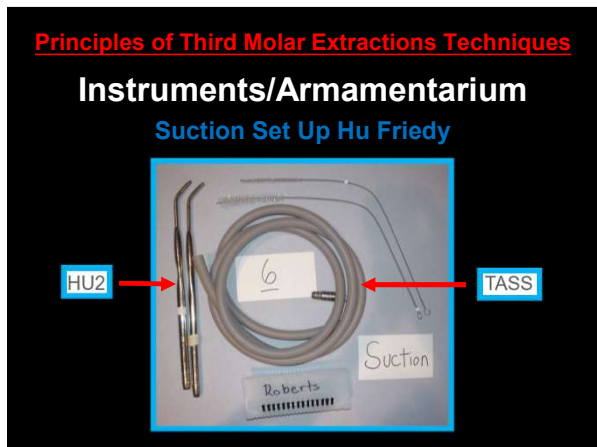
---

---

---

---

---



---

---

---

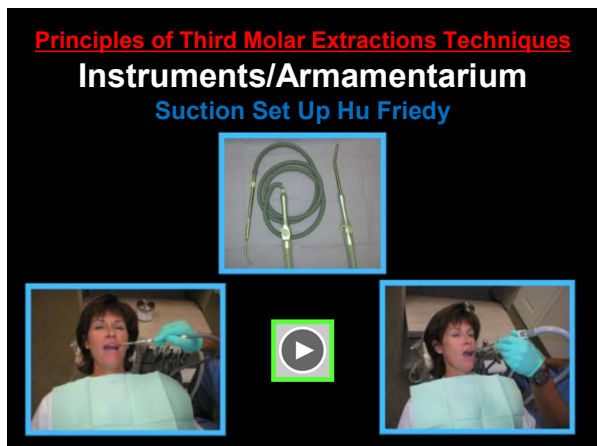
---

---

---

---

---



---

---

---

---


---

---

---

---

**Principles of Third Molar Extractions Techniques**  
**Instruments/Armamentarium**  
Emergency Suction Set Up



Emergency Suction  
4

---

---

---

---

---

---

---

---

**Principles of Third Molar Extractions Techniques**  
**Surgical Handpiece**  
W&H Implantmed 80,000 RPM



W&H SI-1015  
package 3  
includes:  
EM-19 motor  
750 LED  
wireless foot control

SI-1015 4500 \$  
S-12 1700 \$  
S-16 1700 \$

---

---

---

---

---

---

---

---

**Principles of Third Molar Extractions Techniques**  
**Surgical Handpiece**  
Aseptico 80,000 RPM



7000\$

---

---

---

---

---

---

---

---


**Principles of Third Molar Extractions Techniques**

### Surgical Handpiece

Sabra Power 45-S Highspeed Surgical



Impact Air 45 Highspeed Surgical



1000\$

---

---

---

---

---

---

---

---

**Principles of Third Molar Extractions Techniques**

### Surgical Handpiece

Comparison Electric vs Air



---

---

---

---

---

---


---

---

**Principles of Third Molar Extractions Techniques**

### Surgical Burs


Brasseler USA



1701S - Surg fg / skinny bur

1703S - Surg fg /sectioning

703 / sectioning



---

---

---

---

---

---

---

---

**Principles of Third Molar Extractions Techniques**

**Surgicel**  
Dental Supply Company



The image shows various Surgicel products. On the left, there are two boxes and two packets of Surgicel. On the right, a circular inset shows a Surgicel Hemostat being used on a tooth. Below the main images are two smaller images of Surgicel Hemostat packets.

---

---

---

---

---

---

---

---

**Principles of Third Molar Extractions Techniques**

**Bleeding Control**  
Pressure Stops Bleeding



[www.robertsdds.com](http://www.robertsdds.com)

---

---

---

---

---


---

---

---

**Principles of Third Molar Extractions Techniques**

**Bleeding Control**  
Liver Clots



Treatment ?

---

---

---

---

---

---

---

---

Principles of Third Molar Extractions Techniques

Bleeding Control

Blood Thinners

Clinicians can perform most dental procedures safely despite patients' receiving therapeutic anticoagulation.

Recognizing common classes of anticoagulants, incorporating strategies to minimize bleeding, and understanding how commonly prescribed medications in dentistry interact with anticoagulants are essential to practicing safe, comprehensive care.

Treatment in the Dental Practice of the Patient Receiving Anticoagulation Therapy JADA 2019;150(7):602-608

Handwriting lines for notes.

Principles of Third Molar Extractions Techniques

Bleeding Control

Blood Thinners

CAN ANTICOAGULANTS BE CONTINUED AROUND DENTAL PROCEDURES?

Must Consider Both Medical and Dental Risk Profiles High / Moderate / Low

Treatment in the Dental Practice of the Patient Receiving Anticoagulation Therapy JADA 2019;150(7):602-608

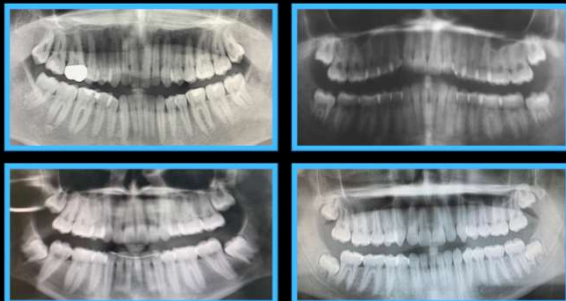Check out Article in Handout

Handwriting lines for notes.

Principles of Third Molar Extractions Techniques

Ideal Cases ?


The ideal time to remove 3rd molars is typically between 13 and 20 years old



Handwriting lines for notes.

**Principles of Third Molar Extractions Techniques**  
An Introduction to Upper Third Molar Impactions

#1 Vertical Impaction      #16 Mesioangular Impaction



- Create Access for Target at CEJ
- Elevate Insert – Push Back - Down and Out

---

---

---

---

---


---

---

---

**Principles of Third Molar Extractions Techniques**  
An Introduction to Upper Third Molar Impactions

Extracting #1



Preview of Video Extracting #1

---

---

---

---

---


---

---

---

**The Three C's of Upper Third Molar Impactions**

Case Selection Case Selection Case Selection



- 1) Roots are 1/2 - 3/4 formed
- 2) Large and Accessible Tuberosity
- 3) Occlusal Surface of 3rd at or below CEJ of 2nd

---

---

---

---

---

---


---

---



Principles of Third Molar Extractions Techniques

### Upper Third Molar Impactions



17 years old

---

---

---

---

---

---


---

---

Principles of Third Molar Extractions Techniques

### Upper Third Molar Impactions

Tooth #1 Vertical Impaction



Create Access for Target at CEJ

---

---

---

---

---

---

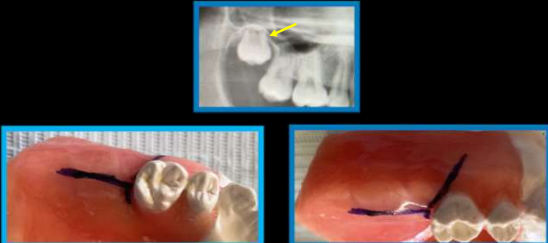
---

---

Principles of Third Molar Extractions Techniques

### Upper Third Molar Impactions

Tooth #1 Vertical Impaction



Flap Design

---

---

---

---

---

---

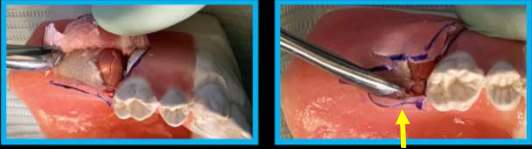
---

---

**Principles of Third Molar Extractions Techniques**

## Upper Third Molar Impactions

Tooth #1 Vertical Impaction



Open The Trap Door

Flap Reflection

---

---

---

---

---

---

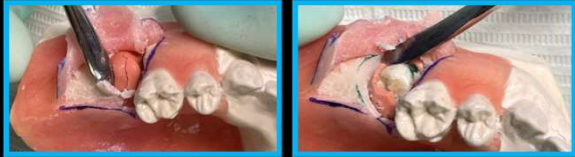
---

---

**Principles of Third Molar Extractions Techniques**

## Upper Third Molar Impactions

Tooth #1 Vertical Impaction



Flap Reflected  
Tooth Exposed with Periosteal

---

---

---

---

---

---


---

---

**Principles of Third Molar Extractions Techniques**

## Upper Third Molar Impactions

Tooth #1 Vertical Impaction



Bone Removal if Needed

---

---

---

---

---

---


---

---

**Principles of Third Molar Extractions Techniques**

### Upper Third Molar Impactions

Tooth #1 Vertical Impaction



Elevator Placement

---

---

---

---

---

---


---

---

**Principles of Third Molar Extractions Techniques**

### Upper Third Molar Impactions

Tooth #1 Vertical Impaction



Elevate Insert – Push Back - Down and Out

---

---

---

---

---

---


---

---

**Principles of Third Molar Extractions Techniques**

### Upper Third Molar Impactions

Tooth #1 Vertical Impaction



Close and Suture

---

---

---

---

---

---

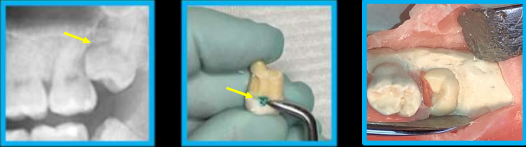
---

---

**Principles of Third Molar Extractions Techniques**

### Upper Third Molar Impactions

Tooth #16 Mesioangular Impaction



- Create Access for Target at CEJ
- Elevate Insert – Push Back - Down and Out

---

---

---

---

---

---

---

---

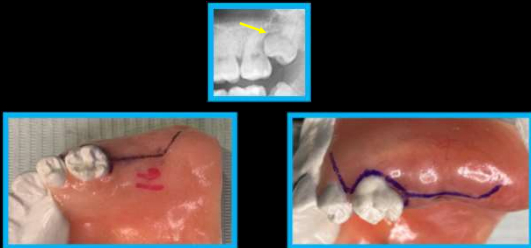
---

---

**Principles of Third Molar Extractions Techniques**

### Upper Third Molar Impactions

Tooth #16 Mesioangular Impaction



Flap Design

---

---

---

---

---

---

---

---

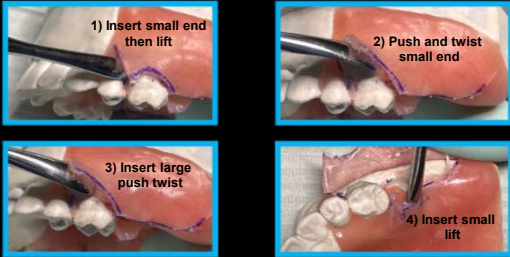
---

---

**Principles of Third Molar Extractions Techniques**

### Upper Third Molar Impactions

Tooth #16 Mesioangular Impaction



Flap Elevation

---

---

---

---

---

---

---

---


---

---

Principles of Third Molar Extractions Techniques

### Upper Third Molar Impactions

Tooth #16 Mesioangular Impaction



Flap Elevation  
Periosteal Demo

---

---

---

---

---

---


---

---

Principles of Third Molar Extractions Techniques

### Upper Third Molar Impactions

Tooth #16 Mesioangular Impaction



Flap Reflected  
Bone Removal Required ?

---

---

---

---

---

---

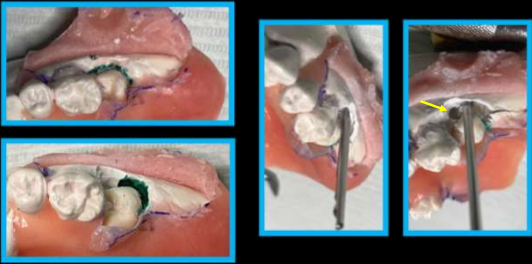
---

---

Principles of Third Molar Extractions Techniques

### Upper Third Molar Impactions

Tooth #16 Mesioangular Impaction



Remove Bone

---

---

---

---

---

---

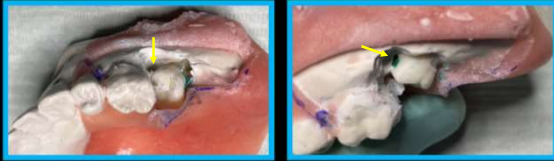
---

---

Principles of Third Molar Extractions Techniques

# Upper Third Molar Impactions

Tooth #16 Mesioangular Impaction



Bone Removed

---

---

---

---

---

---

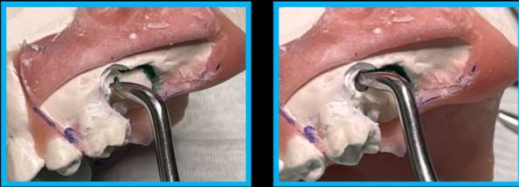---

---

Principles of Third Molar Extractions Techniques

# Upper Third Molar Impactions

Tooth #16 Mesioangular Impaction



Attempt to Elevate  
Unsuccessful

---

---

---

---

---

---

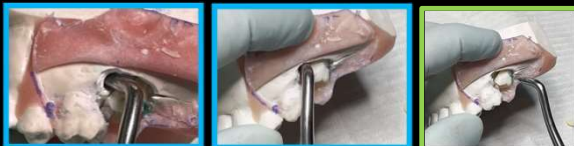---

---

Principles of Third Molar Extractions Techniques

# Upper Third Molar Impactions

Tooth #16 Mesioangular Impaction



Elevate Insert – Push Back - Down and Out

---

---

---

---

---

---


---

---

**Principles of Third Molar Extractions Techniques**

## Upper Third Molar Impactions

Tooth #16 Mesioangular Impaction



Suture and Close

---

---

---

---


---

---


---

---

## An Introduction to Third Molar Impactions Questions ?



David Roberts DDS



ACADEMY OF GENERAL DENTISTRY AGD2021 THE PREMIER MEETING FOR GENERAL DENTISTRY

---

---

---

---

---

---

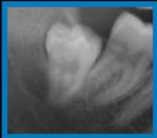
---

---



**Principles of Third Molar Extractions Techniques**

## An Introduction to Lower Third Molar Impactions

#32 Vertical Impaction Coronectomy



#17 Mesioangular Impaction



- Expose Buccal Groove
- Make The Hole Bigger or Object Smaller

---

---

---

---

---

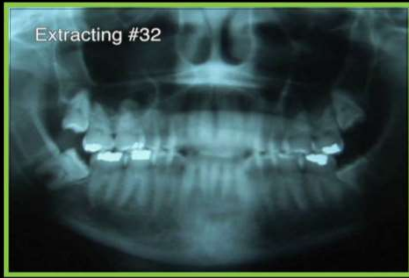---

---

---

**Principles of Third Molar Extractions Techniques**

An Introduction to Lower Third Molar Impactions



Preview of Video Extracting #32

---

---

---

---

---

---

---

---

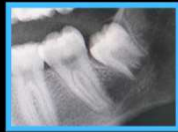**The Three C's of Lower Third Molar Impactions**

Case Selection Case Selection Case Selection

1) Roots are 1/2 - 3/4 formed

2) Above Inferior Alveolar Nerve

3) Occlusal Surface of 3rd above CEJ of 2nd



---

---

---

---

---

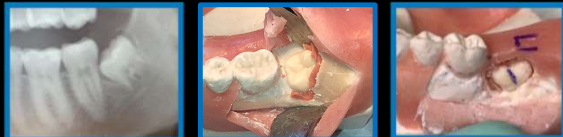---

---

---

**Lower Third Molar Impactions**

Tooth #17 Mesioangular Impaction



**Expose Buccal Groove**

---

---

---

---

---

---

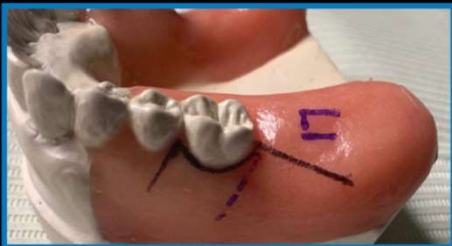---

---



**Lower Third Molar Impactions**

**Tooth #17 Mesioangular Impaction**



Flap Design

---

---

---

---

---

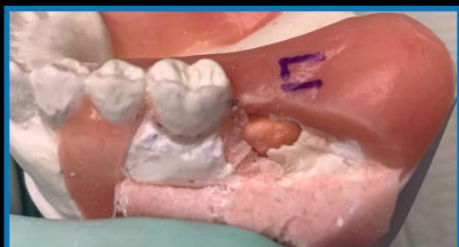---

---

---

**Lower Third Molar Impactions**

**Tooth #17 Mesioangular Impaction**



Reflect Flap

---

---

---

---

---

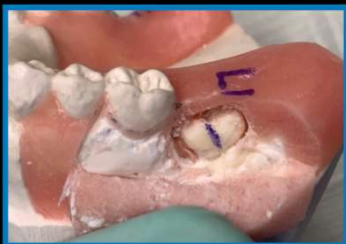---

---

---

**Lower Third Molar Impactions**

**Tooth #17 Mesioangular Impaction**



Remove Bone / Locate Buccal Groove

---

---

---

---

---

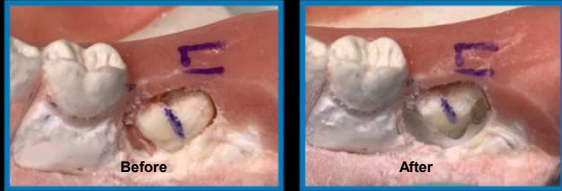---

---

---

**Lower Third Molar Impactions**

**Tooth #17 Mesioangular Impaction**



Lower Buccal Bone  
Cut Buccal and Mesial Troughs

---

---

---

---

---

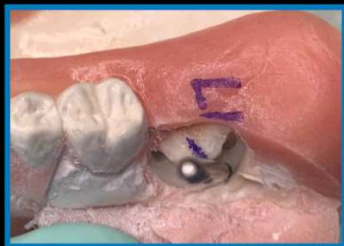---

---

---

**Lower Third Molar Impactions**

**Tooth #17 Mesioangular Impaction**



Bur Parallel to Buccal for Trough

---

---

---

---

---

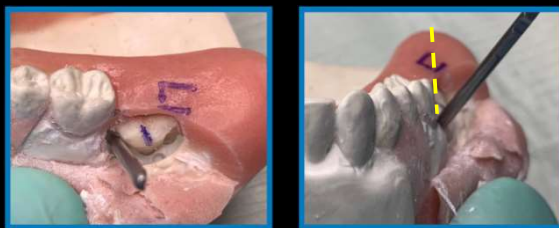
---

---

---

**Lower Third Molar Impactions**

**Tooth #17 Mesioangular Impaction**



Bur Angle for Mesial Trough

---

---

---

---

---

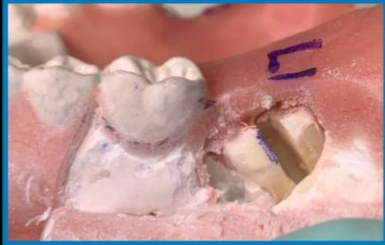---

---

---

**Lower Third Molar Impactions**

**Tooth #17 Mesioangular Impaction**



**Hemisection**

Apically Thru Furcation      Buccal / Lingual 50-75%

---

---

---

---

---

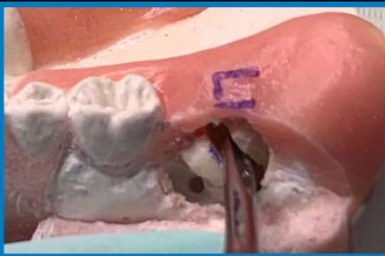
---

---

---

**Lower Third Molar Impactions**

**Tooth #17 Mesioangular Impaction**



**Complete Hemisection**

---

---

---

---

---

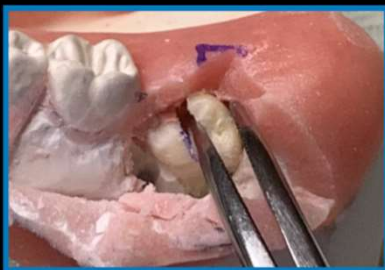---

---

---

**Lower Third Molar Impactions**

**Tooth #17 Mesioangular Impaction**



**Remove Distal**

---

---

---

---

---

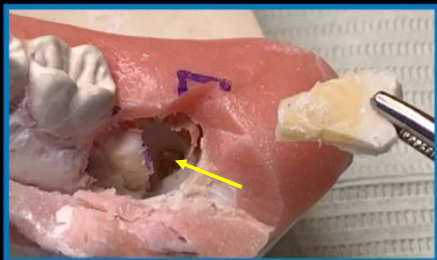
---

---

---

**Lower Third Molar Impactions**

**Tooth #17 Mesioangular Impaction**



Broken Distal Root

---

---

---

---

---

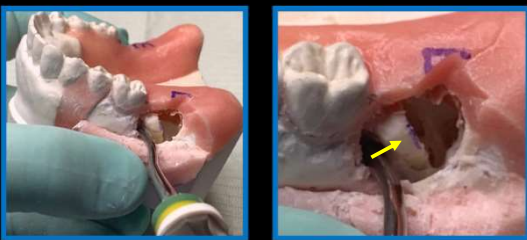
---

---

---

**Lower Third Molar Impactions**

**Tooth #17 Mesioangular Impaction**



Move Mesial Root Distally

---

---

---

---

---

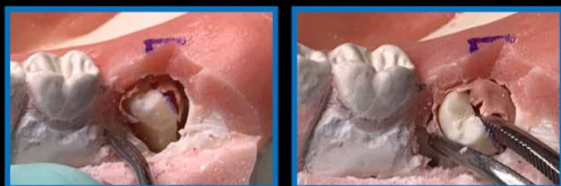---

---

---

**Lower Third Molar Impactions**

**Tooth #17 Mesioangular Impaction**



Remove Mesial Root

---

---

---

---

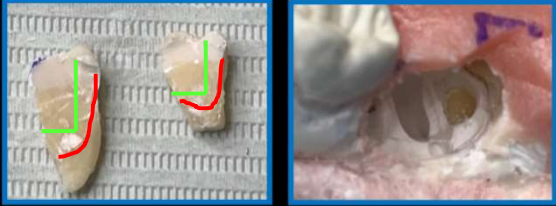
---

---

---

---

**Lower Third Molar Impactions**  
**Tooth #17 Mesioangular Impaction**



Mid-Procedure Assessment

---

---

---

---

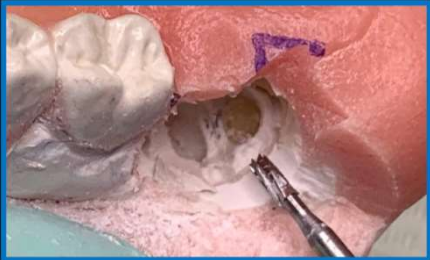
---

---

---

---

**Lower Third Molar Impactions**  
**Tooth #17 Mesioangular Impaction**



Improve Access - Lower Buccal Ridge

---

---

---

---


---

---

---

---

**Lower Third Molar Impactions**  
**Tooth #17 Mesioangular Impaction**



Improve Access - Remove Bone Near Root

---

---

---

---

---

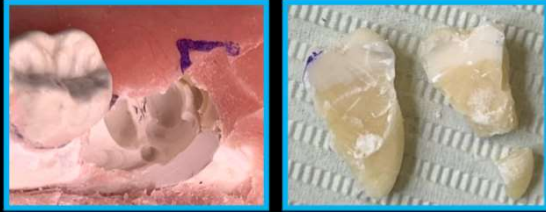
---

---

---

## Lower Third Molar Impactions

Tooth #17 Mesioangular Impaction



Irrigation, Close and Final Assessment

---

---

---

---

---

---

---

---

## An Introduction to Third Molar Impactions Questions ?



David Roberts DDS



---

---

---

---

---

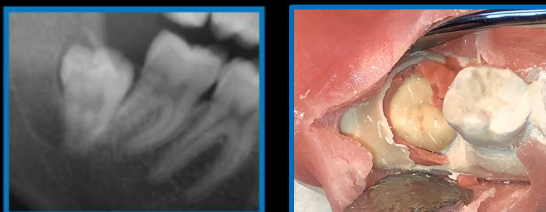
---

---

---

## Lower Third Molar Impactions

Tooth #32 Vertical Impaction / Coronectomy



Expose Buccal Groove  
Cut of Crown Completely  
Root Must be 3mm Below Bone

---

---

---

---

---

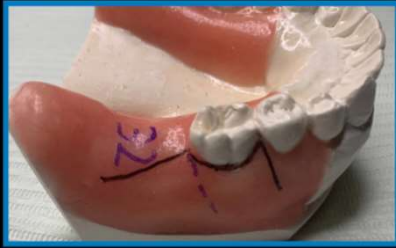
---

---

---

**Lower Third Molar Impactions**

Tooth #32 Vertical Impaction / Coronectomy



Flap Design

---

---

---

---

---

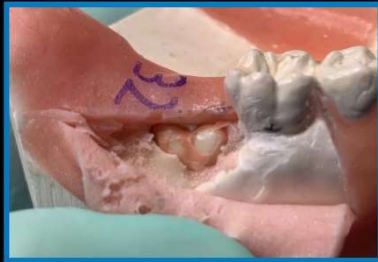---

---

---

**Lower Third Molar Impactions**

Tooth #32 Vertical Impaction / Coronectomy



Flap Reflected

---

---

---

---

---

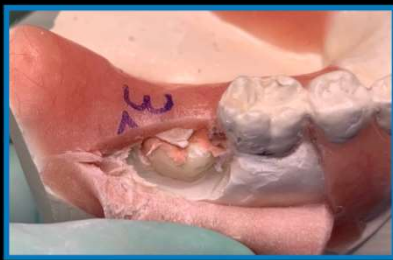---

---

---

**Lower Third Molar Impactions**

Tooth #32 Vertical Impaction / Coronectomy



Initial Trough Cut

---

---

---

---

---

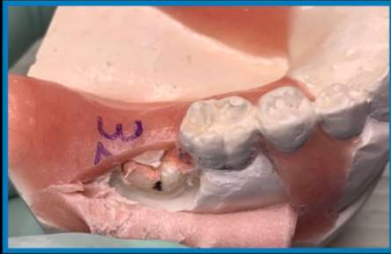---

---

---

**Lower Third Molar Impactions**

Tooth #32 Vertical Impaction / Coronectomy



Identify Buccal Groove

---

---

---

---

---

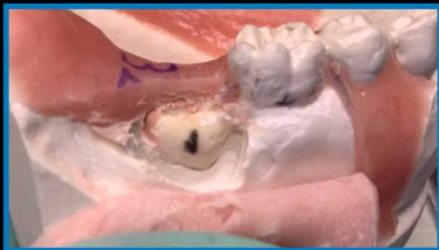---

---

---

**Lower Third Molar Impactions**

Tooth #32 Vertical Impaction / Coronectomy



Expand Flap

---

---

---

---

---

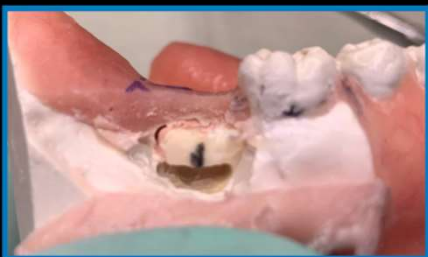---

---

---

**Lower Third Molar Impactions**

Tooth #32 Vertical Impaction / Coronectomy



Horizontal Cut

---

---

---

---

---

---

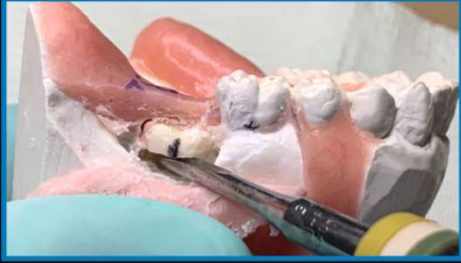---

---



**Lower Third Molar Impactions**

Tooth #32 Vertical Impaction / Coronectomy



Separate Crown from Root

---

---

---

---

---

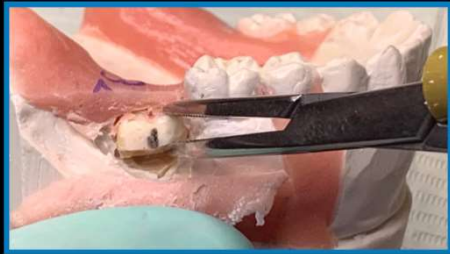---

---

---

**Lower Third Molar Impactions**

Tooth #32 Vertical Impaction / Coronectomy



Remove Crown

---

---

---

---

---

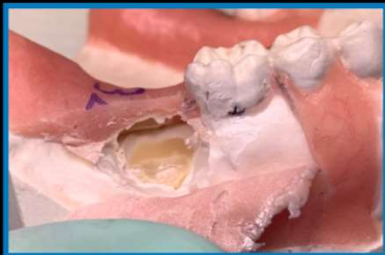---

---

---

**Lower Third Molar Impactions**

Tooth #32 Vertical Impaction / Coronectomy



Inspect Remaining Root

---

---

---

---

---

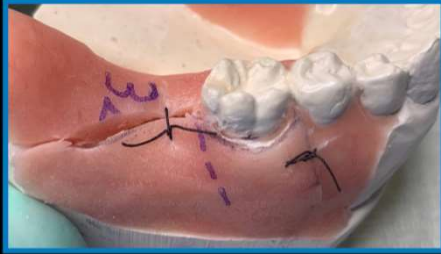---

---

---

## Lower Third Molar Impactions

Tooth #32 Vertical Impaction / Coronectomy



Suture and Close

---

---

---

---

---

---

---

---

## An Introduction to Third Molar Impactions Questions ?



David Roberts DDS



---

---

---

---

---

---

---

---